

## Unusual case report of tardy carpal tunnel syndrome in 40 years old injury wrist with fracture scaphoid

Dr. Ankush Goyal\*, Dr. Manjeet Singh\*\*, Dr. Rakesh Gautam\*\*\*

\*Assistant Professor Unit 1 Orthopaedics MM Medical College Mullana (Ambala) Haryana INDIA

\*\* Professor and Head Orthopaedics Department MM Medical College Mullana (Ambala) Haryana INDIA

\*\*\*Associate Professor Unit 1 Orthopaedics MM Medical College Mullana (Ambala) Haryana INDIA

---

**Abstract:** As per literature the immediate and late carpal tunnel syndrome in colles fracture and other wrist injuries is known but tardy carpal tunnel syndrome in fracture Scaphoid is rare. I am presenting a case of tardy carpal tunnel syndrome in patient with non-union fracture scaphoid with 40 years old injury.

**Keywords:** carpal tunnel syndrome, median nerve, scaphoid

---

### I. Introduction

Fractures of scaphoid are most common amongst wrist fractures, most prevalent in active adolescents. These injuries are prone to complications like non-union and late degenerative changes. The displacement of fracture, avascular necrosis can cause non-union. Symptomatic non-unions have a high probability of degenerative change<sup>[2,3,4]</sup> and even asymptomatic non-unions are likely to develop degenerative changes and eventual symptoms<sup>[5]</sup>. Avascular necrosis is common in the proximal fragment because of its peculiar vascular supply.

Carpal tunnel syndrome (CTS) is the commonest entrapment neuropathy. The dorsal subluxation of carpal bones can cause narrowing of the cross-sectional area of the carpal tunnel thus leading to CTS. Median neuropathy can occur immediately at the time of scaphoid fracture<sup>[6]</sup>, secondary to fracture reduction technique or late associated with immobilization and as a chronic complication related to malunion of the fracture and compromise of the carpal tunnel<sup>[7]</sup> and symptoms are predominantly motor.

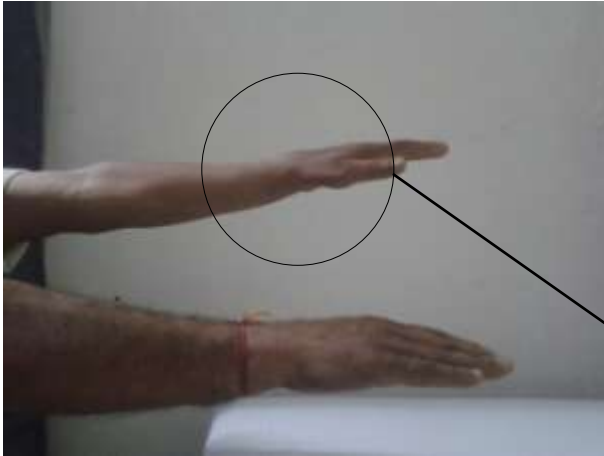
Few cases of delayed CTS have been reported in literature. In 2003 Goyal et al reported a case of delayed CTS after 22 years due to malunited Colle's fracture<sup>[8]</sup>.

Only one case of delayed CTS because of old displaced scaphoid fracture has been reported in literature<sup>[9]</sup>. Here a case is reported which developed CTS after 40 years of scaphoid fracture .

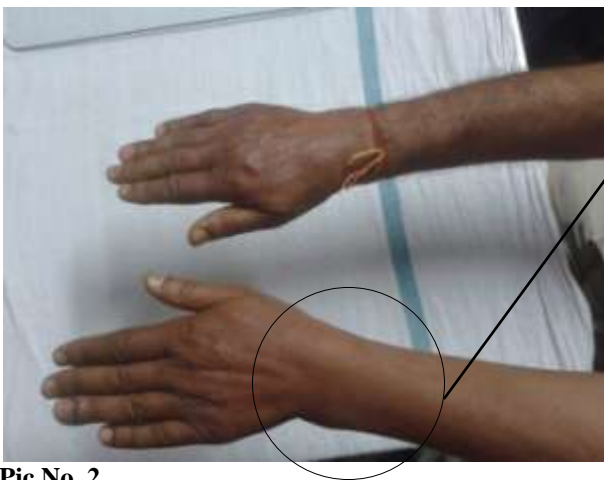### II. Case Presentation

A 61 years old, male presented to our out patients department with the chief complaints of pain, numbness and tingling on the radial side of left hand in the distribution of median nerve for about two months. The symptoms were more at night and in cold weather . The patient gave a history of trauma 40 years back when the patient fell on both of his hands. The patient had pain in left wrist; he was then treated conservatively .The pain subsided in few months time. No radiographs were taken at the time of injury. The patient remained asymptomatic till two months back when the symptoms started developing and gradually increased in severity. There was no history of medical disease i.e. diabetes mellitus, hypothyroidism, peripheral neuropathy and no history of local or generalised joint pain.

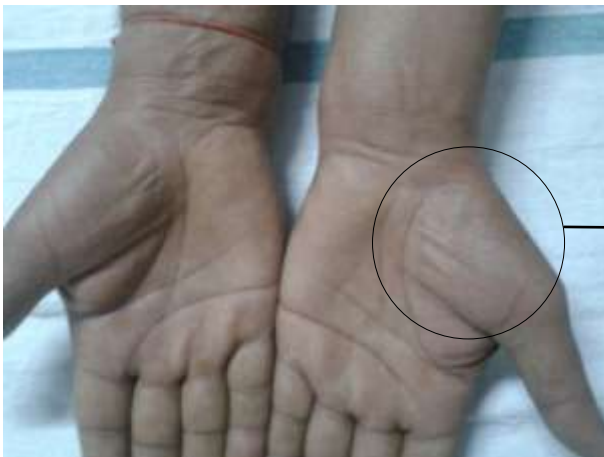Physical examination revealed mild wasting of left thenar muscles and swelling on the dorsal aspect of the wrist and the relationship of the radial and ulnar styloid processes was normal. Tinel's sign and Phalen's test were positive and there was sensory deficit along the distribution of median nerve. Roentograms/CT revealed non-union of scaphoid fracture of left side with osteoarthritic changes. With the above findings patient was diagnosed as left delayed CTS due to old scaphoid fracture. The Patient opted for surgical intervention and surgical release was done.



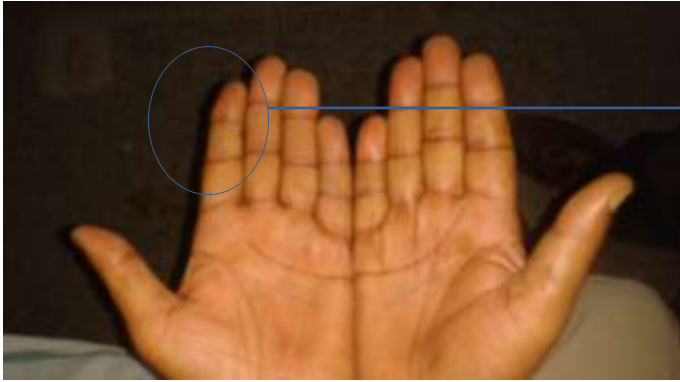
**Pic No.1**



**Pic No. 2**



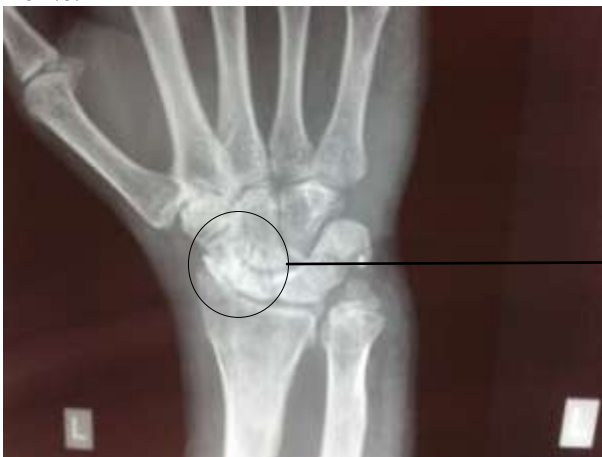Atrophy of  
thenar  
muscles



trophic changes in index finger

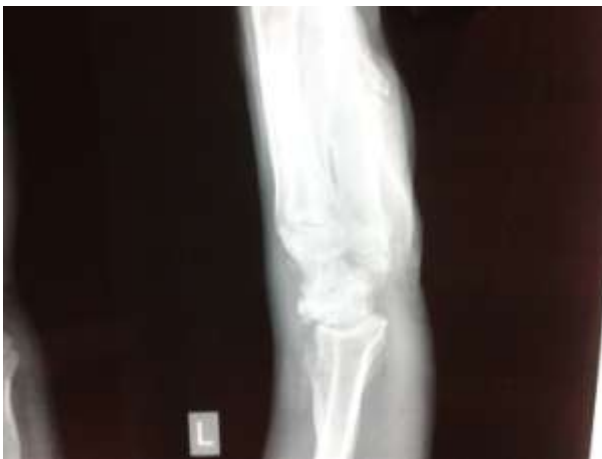**Pic No. 3**

**Pic No. 4**

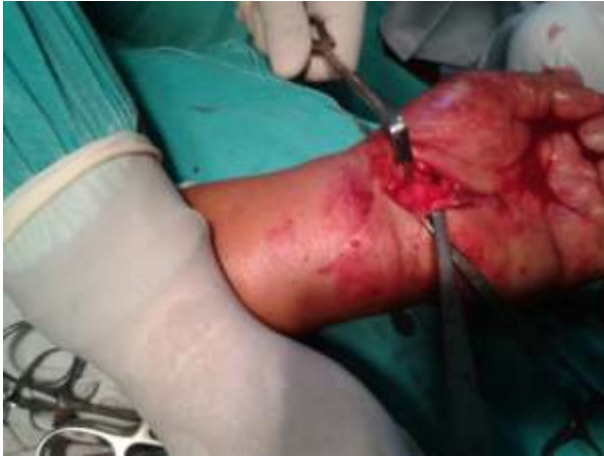

Old Fracture scaphoid

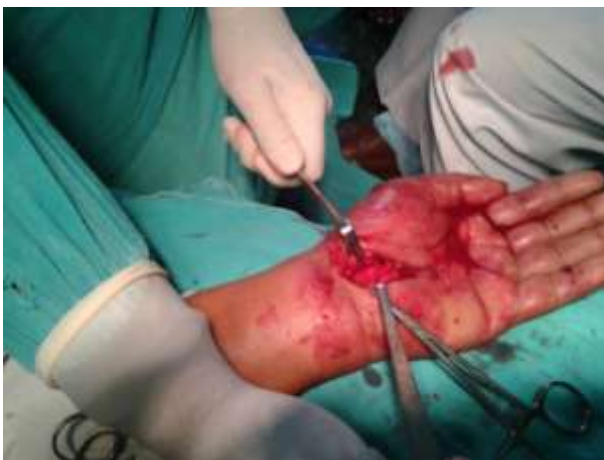X Ray Left wrist AP



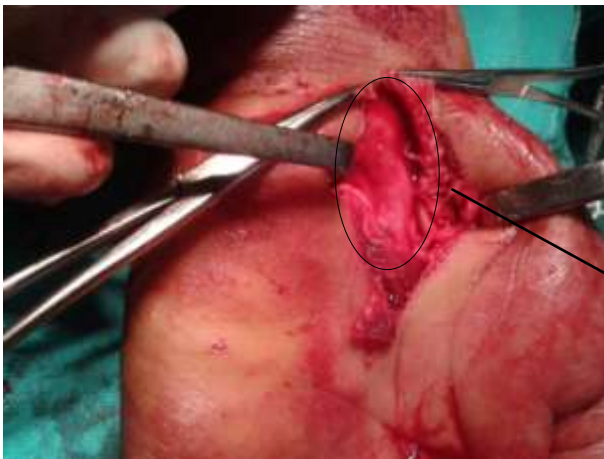X Ray Left wrist Lateral



**Intra-op Pic 1**



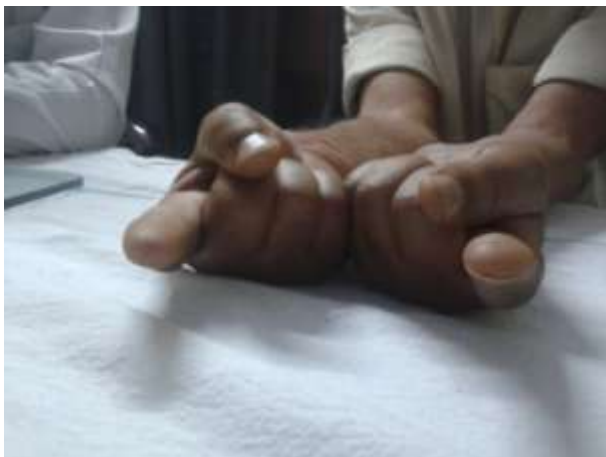**Intra-op Pic 2**



**Intra-op Pic 3**

Median nerve  
decompression

Patient experienced immediate improvement in sensory symptoms.



**Follow up at 6 months**

Pt had almost normal sensory and motor function at follow up.

**III. Discussion**

The Exact mechanism by which patient developed CTS is not clear. We have ruled out all other possible causes for CTS. The likely mechanism for development of CTS may be due to a degenerative change after scaphoid fracture. Generally any physical insult like trauma or fracture can lead to early degenerative changes, which are associated with fibrosis and synovitis<sup>[8]</sup> which may lead to compression, ischemia of nerve and pain. A few cases with the development of CTS after scaphoid fracture has been reported in literature. Olerud et al reported a case of acute CTS, which developed within three hours of fracture scaphoid and fifth metacarpal bone due to compression by a haematoma, which responded dramatically after surgical decompression of the carpal tunnel<sup>[6]</sup>. Lee DJ et al reported a case of delayed CTS due to old displaced fracture of scaphoid, the patient got relief after the excision of the displaced fragment<sup>[7]</sup>. In 1992 Monsivais et al, reported a case of persistent CTS which did not respond to standard surgical release, later it was found that the median nerve was compressed against the flexed distal pole of scaphoid. The patient was treated with internal fixation of scaphoid<sup>[10]</sup>.

Neurophysiological studies are still one of the most valuable techniques to determine the extent of nerve compression or injury. However, in cases where the nerve conduction studies or symptoms are ambiguous<sup>[11]</sup>, ultrasound, CT scan and MRI may help to establish the diagnosis by demonstrating compression of the median nerve. Our patient's CT and roentograms revealed old fracture scaphoid with arthritic changes. The development of CTS in this can be due arthritis causing swelling and irritation of the median nerve. The swelling on the dorsal aspect of the wrist was due to secondary osteoarthritis of carpal bones. The other possible mechanism for development of CTS can be due to the distal fragment avascular necrosis causing compression on the nerve or the carpal tunnel either directly or through the secondary osteoarthritis changes of other carpal bones. So in cases of tardy median nerve palsy the differential diagnosis of old case scaphoid fracture must be considered.

**Abbreviations**

**CTS= Carpal tunnel syndrome AP = Antero Posterior CT Scan = Computed Tomographic Scan MRI = Magnetic Resonance Imaging.**

**References:**

- [1]. Weber E, Chao EY. An experimental approach to the mechanism of scaphoid waist fractures. *J Hand Surg (Am)* 1978; 3 (2): 142-8.
- [2]. Mack GR, Bosse MJ, Gelberman RH et al. The natural history of scaphoid non-union. *J Bone Joint Surg Am.* 1984; 66 (4): 504-9.
- [3]. Milliez PY, Courandier JM, Thomine JM et al. The natural history of scaphoid non-union: A review of fifty-two cases. *Ann Chir Main* 1987; 6 (3): 195-202.
- [4]. Ruby LK, Stinson J, Belsky MR. The natural history of non-union of the scaphoid: A review of fifty-five cases. *J Bone Joint Surg Am.* 1985; 67(3): 428-32.
- [5]. Lindstrom G, Nystrom A. Natural history of scaphoid non-union, with special reference to asymptomatic cases. *J Hand Surg (Br)* 1992; 17(6): 697-700.
- [6]. Olerud C, Lonnquist L. Acute carpal tunnel syndrome caused by fracture of the scaphoid and the 5th metacarpal bones. *Injury* 1984 Nov; 16(3): 198-9.
- [7]. Lee DJ, Fechter J, Schnall SB. Old displaced fracture of the scaphoid. An unusual cause of carpal tunnel syndrome. *Orthop Rev* 1993 Jul; 22 (7): 842-4.
- [8]. Goyal V, Bhatia M, Behari M. Carpal tunnel syndrome after 22 years of Colle's fracture. *Neurol India* 2003; 51: 113-4.
- [9]. Gelberman RH, Menon J. The vascularity of the scaphoid bone. *J Hand Surg Am* 1980; 5A: 508-13.
- [10].

- [11]. Monsivais JJ, Scully S. Rotary subluxation of the scaphoid resulting in persistent carpal tunnel syndrome. *J Hand Surg (Am)* 1992 Jul; 17(4): 642-4.
- [12]. Jarvik JG, Yuen E. Diagnosis of carpal tunnel syndrome: Electrodiagnosis and magnetic resonance imaging evaluation. *Neurosurg Clin N Am* 2001; 12(2): 255-66.
- [13]. Green DP. Russe technique. In: Gelberman RH ed. *The wrist*. Raven New York. 1994:107-18.